



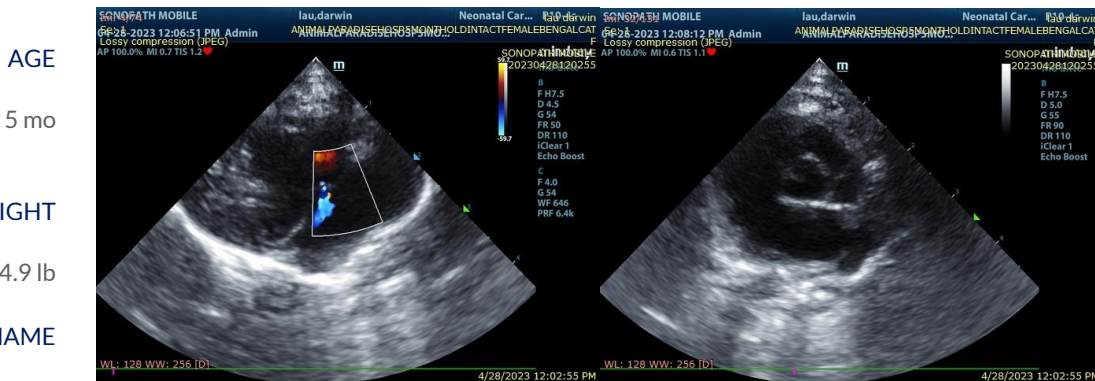
**RESENTING CLINICAL SIGNS**  
**DATE** History: Murmur.  
 4/28/23 **ECHOCARDIOGRAPHIC FINDINGS**  
 2D, M-mode, and Doppler study.  
**PERFORMED BY:** Left atrial size is normal. The mitral valve is normal. Left ventricular wall thickness is normal. Left ventricular internal dimensions are normal. Left ventricular systolic function is hyperdynamic. The aorta and aortic valve appear normal. Right atrial and right ventricular dimensions are normal. The tricuspid valve appears normal, though trace tricuspid regurgitation is present. The pulmonary artery and pulmonic valve appear normal. No shunting lesions are visualized. No pericardial effusion or cardiac masses are seen.  
 Kelly Vazquez  
**INTERPRETED BY**  
 Keith Blass, DVM, MS, DACVIM (Cardiology)  
**PATIENT**  
 Darwin Lau  
 LA/Ao - 1.33  
 IVSd - 3.6 mm  
 LVPWd - 3.6 mm  
 LVIDd - 14.4 mm  
 LVIDs - 5.3 mm  
 FS - 63%  
 LVOT - 1.23 m/s  
 RVOT - 1.17 m/s

**SPECIES ASSESSMENT/RECOMMENDATIONS**

**Feline** The only potential abnormality seen in this exam is trace regurgitation of blood across Darwin's tricuspid valve. It's likely that this represents a normal physiologic variant, however, a very mild form of valvular dysplasia cannot be definitively ruled out. The hemodynamic effects of the regurgitation are negligible, and it's likely to remain that way going forward.  
**BREED**

**Bengal** No therapy is recommended based on this exam.

**SEX** A recheck echocardiogram is recommended if the characteristics of Darwin's murmur change, or if other new physical exam and/or clinical abnormalities suggestive of the presence of cardiac dysfunction develop.  
**FI**



The information and recommendations provided are based on the images presented by the referring veterinarian. No evaluation can be communicated regarding pathology that was not visible in the image/video clips provided.



Thank you for this referral. If the clinical or image interpretation does not parallel your findings or if I can be of any further assistance please contact me.

**DATE**

4/28/23

**Keith Blass, DVM, MS, DACVIM (Cardiology)**  
KeithBlass@gmail.com  
631-804-5754

**PERFORMED BY:**

Kelly Vazquez

**INTERPRETED BY**

Keith Blass, DVM,  
MS, DACVIM  
(Cardiology)

**PATIENT**

Darwin Lau

**SPECIES**

Feline

**BREED**

Bengal

**SEX**

FI

**AGE**

5 mo

**WEIGHT**

4.9 lb

**HOSPITAL NAME**

Animal Paradise  
Hospital

**REFERRING VET**

Dr. Hellworth